Pain Physician 2022; 25:E1095-E1103 • ISSN 2150-1149

Retrospective Study

Comparison of the Effect of Balloon Catheter vs Nucleoplasty vs Balloon Catheter and Nucleoplasty in Patients With Lumbar Spinal Stenosis

Na Eun Kim, MD[1], Jong Bum Choi, PhD[2], Hye Rim Kwon, MD[1], Hee Tae Chung, MD[1], Eun Soo Jang, MD[1], Chang Yik Moon, MD[1], and Byung Gun Kim, PhD[1]

From: [1]Department of Anesthesiology and Pain Medicine, Inha University Hospital, Inha University School of Medicine, Jung-gu, Incheon, Korea; [2]Department of Anesthesiology and Pain Medicine, Ajou University School of Medicine, Suwon, South Korea

Address Correspondence: Byung Gun Kim, PhD Department of Anesthesiology and Pain Medicine, Inha University Hospital, Inha University School of Medicine, Inhang-ro 27, Jung-gu, Incheon, 22332, Korea
E-mail: mirrorcastle@naver.com

Disclaimer: This work was supported by Inha University research grant (number 57848-01)..

Conflict of interest: Each author certifies that he or she, or a member of his or her immediate family, has no commercial association (i.e., consultancies, stock ownership, equity interest, patent/licensing arrangements, etc.) that might pose a conflict of interest in connection with the submitted manuscript.

Manuscript received: 01-03-2022
Revised manuscript received: 04-14-2022
Accepted for publication: 06-14-2022

Free full manuscript: www.painphysicianjournal.com

Background: Nucleoplasty and neuroplasty are often performed in patients with refractory lower back pain when conservative treatment is ineffective. Lumbar spinal stenosis (LSS) is caused by multiple factors; in some cases, a single procedure of nucleoplasty or neuroplasty alone does not provide sufficient treatment effect.

Objectives: This study aimed to investigate and compare the pain relief and pain-free interval among patients with LSS who underwent nucleoplasty, neuroplasty, and combined balloon neuroplasty and nucleoplasty.

Study Design: Retrospective study.

Setting: In-ha University hospital pain clinic.

Methods: This is a retrospective study of the medical records and survey of 98 patients with LSS who visited a pain clinic between 2019 and 2020 and underwent nucleoplasty, neuroplasty, and combined balloon neuroplasty and nucleoplasty. Patients with disc height < 50% of the adjacent disc on magnetic resonance imaging and those with moderate and severe extraforaminal stenosis were excluded. Thus, 60 patients who underwent nucleoplasty (n = 20), neuroplasty (n = 20), and combined balloon neuroplasty and nucleoplasty (n = 20) for LSS were analyzed. The patients were instructed to rate their pain intensity via an 11-point numeric rating score (NRS) before and after the procedure. The Korean version of the Oswestry Disability Index (ODI) questionnaire was checked before and after the procedure.

Results: The pain intensity decreased to NRS 3 ± 0.14 and 1.85 ± 0.19 in the nucleoplasty and combined balloon neuroplasty and nucleoplasty groups, respectively, indicating a significant difference ($P = 0.003$). ODI was significantly decreased after the procedure compared with that before the procedure in all groups. After the procedure, ODI decreased to 13.89 ± 0.20 and 11.21 ± 0.33 in the nucleoplasty and combined balloon neuroplasty and nucleoplasty groups, respectively, with a significant difference between the 2 groups ($P < 0.05$). The patients in the nucleoplasty group achieved pain relief for 4.93 ± 1.22 months after the procedure, whereas those in the balloon neuroplasty group achieved pain relief for 5 ± 1.37 months. In the combined balloon neuroplasty and nucleoplasty group, pain relief was maintained for 10.2 ± 1.11 months ($P = 0.003$).

Limitations: The pain was assessed with NRS without considering the patients' pain medication. There may be differences in the outcome of the procedure depending on the surgeon.

Conclusion: The pain reduction effect was greater and was retained for a longer period with combined balloon neuroplasty and nucleoplasty than with nucleoplasty or neuroplasty alone.

Key words: Neuroplasty, nucleoplasty, balloon catheter, spinal stenosis, Numeric Rating Score, Oswestry Disability Index, pain relief, pain-free interval

IRB Approval: This retrospective study was approved by our institutional ethics committee.

Pain Physician 2022: 25:E1095-E1103

Lumbar spinal stenosis (LSS), which is the narrowing of the spinal canal space, is caused by hypertrophy of the surrounding structures, i.e., the ligaments and facet joints, and extrusion of the disc (1). In the case of refractory LSS that does not respond to conservative treatment, such as drug treatment and physical therapy, epidural steroid injection is administered (2). However, patients with infections or underlying diseases can only undergo repeated epidural steroid injections for a limited number of times, and if there is accompanying epidural adhesion, sufficient therapeutic effect is unlikely with injection treatment alone (3).

With the development of various devices and drugs, balloon neuroplasty or nucleoplasty, which can effectively relieve epidural adhesion, has been widely practiced until recently. Balloon catheter, first introduced in 2013, provides a greater degree of pain relief and longer pain-free period than the existing balloonless catheter (4). The coblation technique of nucleoplasty reduces intradiscal pressure and the activity of phospholipase A2 (PLA2), thereby reducing pain due to disc and degenerative changes (5).

However, the pain control effect of nucleoplasty alone and neuroplasty alone may be limited in the case of refractory lower back pain, which has multiple causes. Lumbar nucleoplasty has limited indications and a risk of discitis after the procedure; meanwhile, neuroplasty has drawbacks such as a short treatment period and recurrence rate (6). Patients with persistent radiating pain after nucleoplasty obtain significant pain relief after neuroplasty. Thus, in cases of severe pain or severe disc extrusion on magnetic resonance imaging (MRI), with both central and foraminal stenosis, nucleoplasty and neuroplasty are performed together.

This study aimed to investigate and compare the pain relief and pain-free interval among patients with LSS who underwent nucleoplasty, neuroplasty, and combined balloon neuroplasty and nucleoplasty.

Methods

Study Design and Patients

This study was approved by the Institutional Review Board (IRB 2021-04-037) of the Inha University Hospital, Incheon, Korea (IRB approval number: 2021-04-037). The requirement for informed consent was waived due to the retrospective nature of the study design.

This was a retrospective study of patients who visited our institution and diagnosed with LSS at our pain clinic between January 2019 and January 2020. Patient information was obtained through electronic medical records. The study included patients with refractory spinal stenosis who underwent neuroplasty using an inflatable balloon catheter (ZiNeu®, JUVENUI, Seoul, Korea) and/or nucleoplasty (YES DISC®, Mcare, Seoul, Korea) at our institution.

Patients aged 50-80 years who visited the pain clinic for chronic back and leg pain, diagnosed with LSS with imaging tests (MRI and computed tomography [CT]), with poor pain relief after > 3 months of treatment (drugs and/or epidural steroid injection treatment), and with disc height > 50% of the adjacent disc were included in the study. To apply the common indications for nucleoplasty and neuroplasty through MRI or CT in all patients, the patients with disc sequestration and disc height < 50% of the adjacent disc, those with spinal stenosis due to severe facet hypertrophy or severe ligamentum flavum hypertrophy, those with moderate or severe extraforaminal stenosis determined through MRI or CT, those with incomplete medical records, those who refused to participate in the study, those with extreme pain (11-point numeric rating score [NRS-11] ≥ 10, e.g., vascular pain, cancer pain, or pain from other causes that could not be excluded), those with allergic reactions to drugs used in the procedure (including steroids and contrast agents), pregnant women, those at risk of injection site infection, those who had undergone back surgery, those with unstable mental and physical conditions and/or mental disease, those with BMI > 40, and those with severe neurological abnormality, proximal weakness, or abnormal keyboard reflex were excluded. Among 98 patients, 38 patients were excluded based on the above criteria; thus, 60 patients were included in the study (Fig. 1).

Interventions

All surgical procedures were carried out by a single expert in the operating room. A prophylactic antibiotic was injected 30 min before the procedure. The blood pressure, electrocardiogram, and pulse oximetry were monitored during the procedure. The patients were positioned in the prone position with a pillow placed under the pelvis to reduce the lumbar lordotic curve. All patients received intravenous sedation prior to the procedure to ensure their comfort. When radiating pain was significant due to foraminal stenosis, balloon catheter neuroplasty was performed; nucleoplasty was performed when decompression was required due to disc herniation; when both of the above were judged

to be the cause of the pain, the 2 procedures were combined.

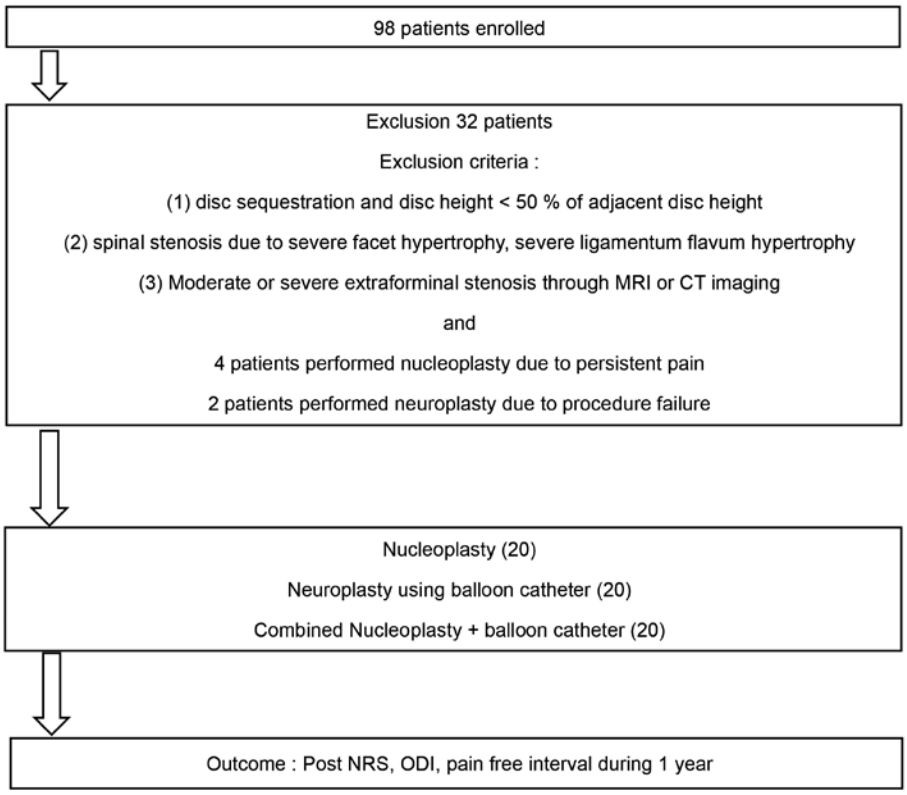

Fig. 1. *Consort flow diagram of patients in this study.*

Nucleoplasty

Nucleoplasty using YES DISC® (Mcare) was performed in the operating room on all patients. The patients were positioned in the prone position with a pillow under the abdomen. Local anesthetic (10 mL 1% lidocaine) was injected into the superior articular process at the target level. The introducer needle was positioned posterolaterally to the disc via fluoroscopic guidance. After adjusting the introducer needle to be located at the target site in the disc, the coblation wand was slowly inserted into the introducer needle. Coblation was performed in a 360° direction at 9–25 Hz for 10-15 seconds. After the procedure, the vital signs and neurological symptoms of the patients were closely observed in the recovery room (Fig. 2).

Percutaneous Adhesiolysis Using an Inflatable Balloon Catheter

The patients were positioned in a prone position with a pillow under the abdomen. After sterile preparation, 1% lidocaine was injected into the skin and soft tissue at the site of the sacral hiatus. A guided needle was introduced into the sacral hiatus, and a diluted contrast agent (Omipaque; Nycomed Imaging, Oslo, Norway) was used to confirm that the needle was in the epidural space via fluoroscopy. The filling defect was reconfirmed through an epidurogram, and the balloon catheter was placed in the area corresponding to the patient's pain area according to the magnetic resonance image. As shown in Fig. 2, epidural adhesiolysis was carefully performed, and during the procedure, the patient's vital signs and responses were continuously monitored. The catheter was placed in the neural foramen as much as possible, and the balloon time was within 5 seconds. Subsequently, successful adhesiolysis was confirmed using a contrast agent, and 2 mg dexamethasone and 2.5 mL 0.25% ropivacaine were injected at each level.

After the procedure, a sterile dressing was applied at the area of the sacral hiatus, and the treatment area was sealed with an adhesive. In the recovery room, the patient's vital signs and side effects, such as motor and sensory abnormalities, were closely monitored, and when there were no specific abnormalities, the patient was moved to the ward.

Outcome Assessments and Follow-Up

All patients were asked to rate their pain via the NRS-11 (0 = no pain to 10 = worst possible pain) before the procedure and the day after the procedure. Additionally, the Korean version of the Oswestry Disability Index (ODI) questionnaire (10 items, range 0-100; 0 = no disability) was checked before the procedure and

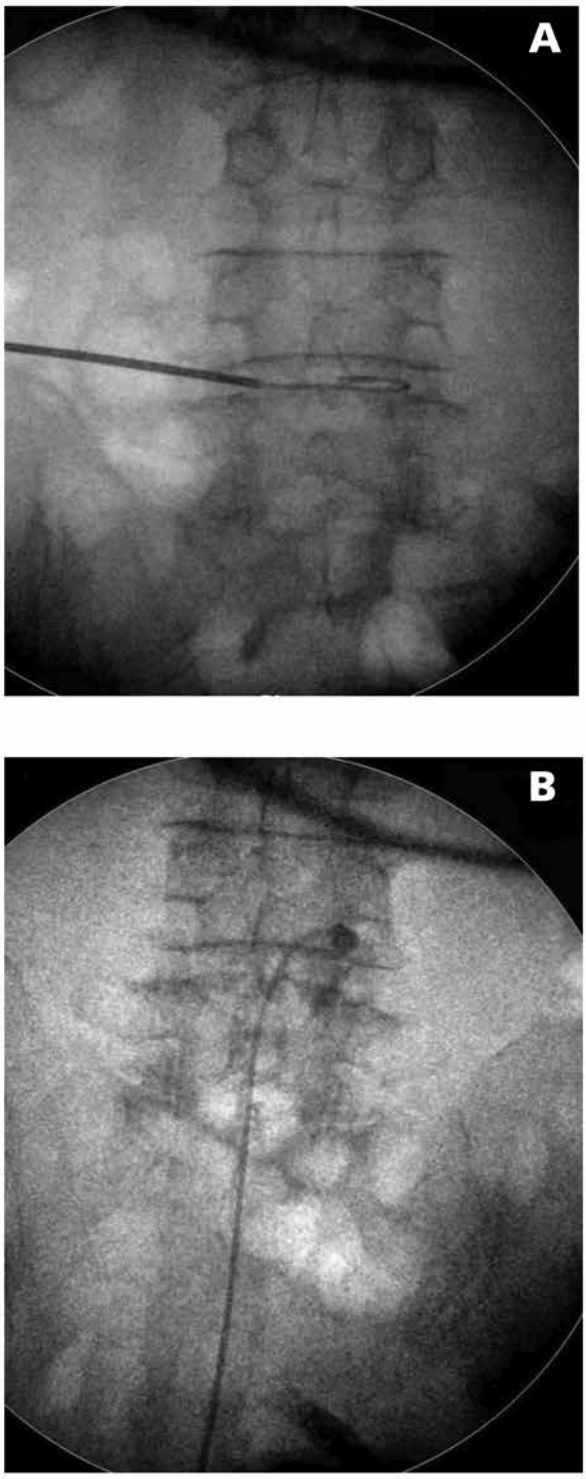

Fig. 2. *A) Nucleoplasty with fluoroscopic guided. B) Percutaneous epidural adhesiolysis with balloon catheter.*

the day after the procedure. Patient information, MRI findings, treatment duration, and vital signs were obtained through the patient's electronic medical records. The patients were divided into 3 groups: nucleoplasty group, i.e., those who underwent nucleoplasty alone (n = 20); balloon neuroplasty groups, i.e., those who underwent balloon decompression neuroplasty (n = 20); combined balloon neuroplasty and nucleoplasty group, i.e., those who underwent both nucleoplasty and balloon decompression neuroplasty (n = 20). The pain intensity and ODI were assessed 1 year after the procedure, and if it was impossible to obtain these parameters at the outpatient clinic, they were assessed through a telephone call.

Statistical Analyses

Statistical analyses were performed using SPSS version 21 (IBM Corp., Armonk, NY, USA), and each measurement was expressed as mean ± standard deviation. The Kruskal-Wallis test and Mann-Whitney U test were used to compare the effects of treatment in each group. To determine the effectiveness of treatment in each group, the Wilcoxon signed-rank test was used. A *P*-value < 0.05 was considered statistically significant. Age, gender, procedure level, and degree of spinal stenosis were analyzed using the Kruskal-Wallis test, and the procedure time and preoperative NRS were analyzed using a one-way analysis of variance (generalized linear model). Simple regression analysis was performed to identify the variables that affected the postoperative NRS, postoperative ODI, and procedure time.

Results

In total, 60 patients underwent the procedure, and no complications such as dural puncture or bleeding occurred during the procedure. In 4 patients who underwent lumbar nucleoplasty and additional procedures because of persistent pain until the day after the procedure, balloon decompression was unsuccessful due to severe stenosis in 2 patients.

The demographic data of the patients are shown in Table 1. Except for the procedure level, there was no difference among the 3 groups. The patients in the balloon neuroplasty groups had a mean procedure level of 2.45 ± 0.15 ($P < 0.05$).

In all 3 groups, the NRS-11 significantly decreased after the procedure compared with the score before the procedure. The nucleoplasty group showed a statistically significant postoperative decrease in NRS (3 ±

0.14) compared with the preoperative NRS (6.47 ± 0.21). The balloon neuroplasty group showed a significant postoperative decrease in NRS (2.7 ± 0.4418) compared with the preoperative NRS (5.3 ± 0.28). In the combined balloon neuroplasty and nucleoplasty group, the postoperative NRS decreased to 1.85 ± 0.1956, compared with the preoperative NRS (6.4 ± 0.28) ($P < 0.05$) (Fig. 1).

A comparison of the groups showed that the pain intensity decreased to NRS 3 ± 0.14 and 1.85 ± 0.19 in the nucleoplasty and combined balloon neuroplasty and nucleoplasty groups, respectively, indicating a significant difference ($P = 0.003$). In addition, ODI was significantly decreased after the procedure in all groups compared with ODI before the procedure. After the procedure, the ODI decreased to 13.89 ± 0.20 and 11.21 ± 0.33 in the nucleoplasty and combined balloon neuroplasty and nucleoplasty groups, respectively, with a significant difference between the 2 groups ($P < 0.05$) (Figs. 3A,3B).

The pain-free interval was defined as the duration with an NRS score ≤ 4 or during which no additional treatment other than drugs was used after the procedure. The patients in the nucleoplasty and balloon neuroplasty groups had pain-free intervals of 4.93 ± 1.22 and 5 ± 1.37 months, respectively, after the procedure. The combined balloon neuroplasty and nucleoplasty group had a pain-free interval of 10.2 ± 1.11 months ($P = 0.003$) (Fig. 4).

If pain occurred on the day of the procedure, NSAIDs were administered, and there were no complications, such as infection or bleeding, in the outpatient follow-up 2 weeks after the procedure. Even when the 2 procedures were combined, the procedure time increased to 53.5 ± 3.9 minutes, but there were no complications.

In the nucleoplasty group, one patient (5%) underwent surgery within one year after the procedure and 4 patients (20%) who did not feel pain relief within one month after the procedure. In neuroplasty group, one patient (5%) underwent surgery within one year after the procedure. In total, 8 patients (40%), including those who underwent surgery, showed no significant pain reduction within one month. In the neuroplasty and nucleoplasty group, 4 patients (20%) underwent surgery within one year, and 5 patients (25%), including those who underwent surgery, had no significant pain reduction within one month.

In each procedure, a simple regression analysis was performed to determine the variables that affected NRS, ODI, and procedure time, and no variable showed a significant association with the 3 outcomes (Table 2).

Table 1. *Comparison of patient characteristics before procedure.*

Parameter	Nucleoplasty	Balloon	Nucleoplasty + Balloon	*P* value
Age,y	52.7 ± 2.8	61.3 ± 3.1	55.0 ± 3.2	.053
Gender ratio (M/total)	0.4 ± 0.1	0.4 ± 0.1	0.5 ± 0.1	.799
Target level	1.7 ± 0.1	2.4 ± 0.1	1.8 ± 0.1	.001
Procedure Time (min)	46.0 ± 2.7	48.2 ± 2.9	53.5 ± 3.9	.259
Stenosis grade				
Central stenosis	2.0 ± 0.1	1.7 ± 0.1	2.1 ± 0.1	.698
Foraminal stenosis	2.2 ± 0.1	2.1 ± 0.1	2.3 ± 0.1	.602
Pain intensity (NRS)	6.2 ± 0.2	5.6 ± 0.3	6.3 ± 0.2	.242
Pain site (lower back)	15 (20)	15 (20)	16 (20)	.5789
Pain site (leg)	12 (20)	15 (20)	14 (20)	.750
ODI	31.4 ± 0.9	32.1 ± 0.5	31.8 ± 0.7	.398
Pain-free interval time (month)	4.9 ± 1.2	5 ± 1.3	10.2 ± 1.1	0.003

Data are expressed in numbers, means ± standard error deviation,
NRS: numeric rating scale.
Neuropalsty was performed using a balloon catheter.
Central stenosis: mild: 1, moderate: 2, severe: 3.
Foraminal stenosis: mild: 1, moderate: 2, severe: 3.

Discussion

The changes in pain intensity and ODI were confirmed in 60 patients with LSS who underwent nucleoplasty, neuroplasty, and combined balloon neuroplasty and nucleoplasty. In all procedures, the pain intensity and ODI decreased significantly after the procedure; however, the most significant decrease in pain and ODI was in the combined balloon neuroplasty and nucleoplasty group. In addition, when neuroplasty and nucleoplasty were performed together, the pain relief lasted for more than 10 months.

In the United States, more than 200,000 patients older than 65 years have LSS, and surgical treatment is considered for these patients (7). LSS occurs due to various causes, such as disc herniation, peripheral ligaments, and facet hypertrophy. The treatment of LSS includes drugs and epidural block, but there are limitations due to problems such as changes in adrenal function and infection, which may occur during repeated steroid injections in the elderly (8). In addition, if there

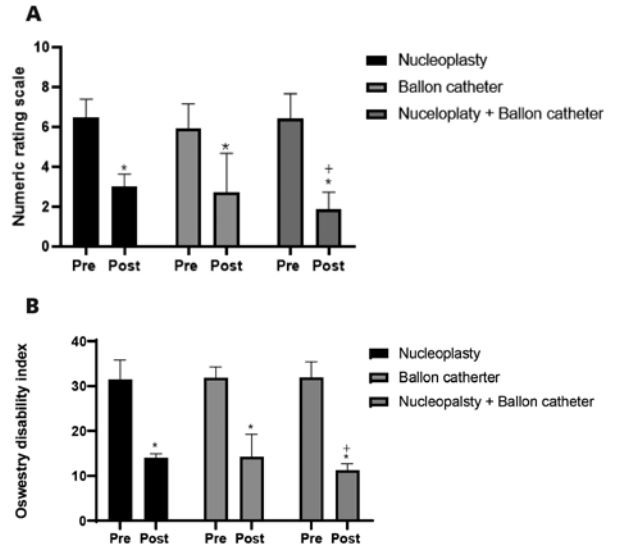

Fig. 3. *A. Data are presented as pain intensity using numeric rating scale. Each point represents the mean ± SE of values. Each group decreased the intensity of pain compared to before the procedure (*P < 0.05). There was a statistically significant difference in the degree of pain relief in the nucleoplasty group compared to the nucleoplasty and neuroplasty with balloon catheter (+P < 0.05). B. Data are presented as the Oswestry disability index. Each point represents the mean ± SE of values. ODI was decreased compared to before the procedure in each group (*P < 0.05). There was a statistically significant difference in ODI in the nucleoplasty group compared to the nucleoplasty and neuroplasty with balloon catheter (+P < 0.05).*

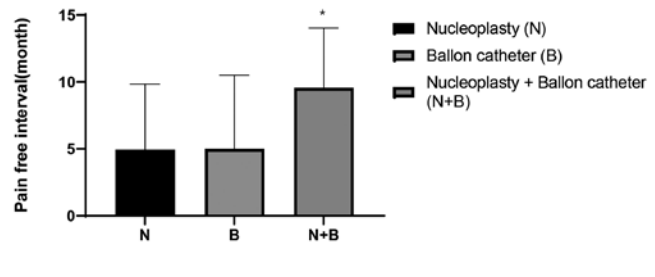

Fig. 4. *After the procedure, the pain was maintained below the NRS 5 points, or the time required for no additional treatment was indicated. Each points represents the mean ± SE of values. The pain-free interval was significantly longer in the group treated with nucleoplasty and balloon catheter compared (10.2 ± 1.11) to the group treated with only nucleoplasty (4.93 ± 1.22) or balloon catheter (5 ± 1.37) (*P < 0.05).*

is a structural change in the spine or epidural adhesion due to degeneration, effective treatment is difficult to achieve with epidural injection alone. Many instruments have been designed and implemented for invasive procedures, such as neuroplasty and nucleoplasty.

Since January 2000, nucleoplasty using the coblation technique has been recommended for the treatment of chronic back pain (9). It is based on the principle of generating heat through the vibrational motion of vibrational ions using high-frequency heat, and it is widely used in the ablation of tumors and dysfunctional tissues, in addition to percutaneous nucleoplasty (10).

Compared with intradiscal electrothermal therapy, coblation is used to achieve disc shrinkage and absorb heat through the plasma layer. Therefore, it can be performed at a relatively low temperature (40-70°C) and has the advantage of causing lesser tissue damage. According to a meta-analysis of nucleoplasty studies, pain relief after nucleoplasty significantly decreased after one day, and the pain reduction was maintained for more than 24 months (11). In this study, in 20 patients who underwent nucleoplasty, the pain was reduced immediately after the procedure, but the pain recurred within one month after the procedure, or surgical treatment was required in 25% of the patients. However, there are cases where the pain slowly decreases after approximately one month (11). In a previous study, there were no significant differences in the MRI findings immediately after nucleoplasty compared with the finding before the procedure, as there is no immediate neural decompression after the procedure, and there is a procedure failure of 25% after the procedure (12). In addition, the indications for nucleoplasty are stricter than those for percutaneous neuroplasty; thus, its use is often limited in the clinical setting.

Percutaneous epidural adhesiolysis with neuroplasty is often performed when pain persists, even in the treatment of epidural blocks or if pain occurs due to epidural adhesions and fibrosis (13). Since it was first introduced by Racz in 1989, neuroplasty has been used to relieve the pain of epidural adhesions and fibrosis through adhesiolysis, and the balloon-inflatable catheter, first introduced in 2014, has the advantage of directly decompressing the lesion area by expanding the balloon attached to the tip of the instrument (4). In the current study, neuroplasty was performed using a balloon catheter, and the group that used

Table 2. *Univariate regression (beta) analyses performed on the relationship between post-NRS, post-ODI, and procedure time in the group (nucleoplasty, balloon catheter, nucleoplasty plus balloon catheter).*

	Variable	Post-NRS		Post-ODI		Procedure time (min)	
		Beta (95% CI)	*P* value	Beta (95% CI)	*P* value	Beta (95% CI)	*P* value
Nucleoplasty	Age	0.012	0.412	-0.002	0.907	0.290	0.282
	Central stenosis	-0.100	0.648	0.300	0.252	6.000	0.135
	Foraminal stenosis	0.153	0.572	0.508	0.110	8.952	0.067
	Pre-ODI	0.051	0.154	-	-	-0.837	0.222
	Pre-NRS	-	-	0.296	0.139	-	-
Balloon catheter	Age	-0.025	0.463	0.036	0.686	-0.147	0.535
	Central stenosis	-10.484	0.050	1.210	0.563	-10.484	0.050
	Foraminal stenosis	1.507	0.723	-1.758	0.257	1.507	0.723
	Pre-ODI	0.240	0.213	-	-	-1.239	0.354
	Pre-NRS	-	-	0.990	0.294	3.087	0.222
Nucleoplasty + Balloon catheter	Age	0.009	0.584	-0.004	0.857	0.032	0.915
	Central stenosis	-0.275	0.378	0.412	0.310	-2.157	0.715
	Foraminal stenosis	0.333	0.241	0	> 0.999	2.333	0.668
	Pre-ODI	0.026	0.697	-	-	-1.196	0.335
	Pre-NRS	-	-	0	> 0.999	-1.667	0.608

NRS, Numeric Rating Scale; ODI, Oswestry Disability Index; CI, confidence interval.

the balloon catheter had a significant difference in NRS and ODI after the procedure compared with those who used a balloon-less catheter (4). When the procedure was performed using a balloon catheter, the reduction in pain immediately after the procedure was similar to that of nucleoplasty, and the pain relief duration was approximately 5 months. However, compared with nucleoplasty, it was possible to treat multiple areas in a shorter time, and it had the advantage of a wider range of indications (14,15).

In the current study, a balloon catheter was placed in the anterior epidural space to confirm the posterior surface of the disc and empty space. Subsequently, nucleoplasty was performed, and neuroplasty was performed again for adhesiolysis; its advantages were confirmed in terms of effectiveness and safety.

Combined balloon neuroplasty and nucleoplasty resulted in a significant reduction in pain and a pain relief period of more than 10 months immediately after the procedure compared with the groups that underwent either procedure; this could be due to a synergistic effect between the 2 procedures.

LSS is a degenerative disease caused by multiple causes, and treatment may be limited to just one treatment. In the case of central stenosis, decompression and antinociceptive effect through nucleoplasty are possible, and for foraminal stenosis, ischemic and congestive changes were reduced through adhesiolysis using a balloon catheter.

The coblation technique of nucleoplasty reduces PLA2, and as noted earlier, it also reduces the disc shrinkage effect (5). PLA2 is an inflammatory cytokine, and coblation has been suggested to reduce the pressure in the disc, reduce the activity of PLA2, and relieve pain. The coblation technique is used to remove volume tissue through molecular dissociation. However, the mechanism by which this is achieved is unclear, and it takes approximately a month for sufficient disc shrinkage to occur, which is a limitation of this technique (5). This mechanism is effective in managing chronic disc pain in patients with LSS.

Neuroplasty using a balloon catheter was first introduced in 2013; it is a procedure that uses balloons to relieve neural compression and adhesiolysis as well as congestion of blood flow in the spinal canal, which is the primary cause of neurogenic claudication. It is suggested that these 2 treatments can effectively reduce nociceptive receptors in the epidural space and in the disc, resulting in a synergistic effect in pain relief. Neuroplasty using a balloon catheter is difficult to perform when a caudal approach is limited or when surgery is performed, and a therapeutic effect may not be observed when there is severe compression due to a large disc.

In this study, for combined balloon neuroplasty and nucleoplasty, a caudal approach was employed for the neuroplasty catheter; the catheter was positioned in the anterior epidural space, the posterior side of the disc was verified using a contrast medium, and nucleoplasty was performed. Nucleoplasty can be performed after confirming the posterior wall of the disc, allowing percutaneous decompression to be performed safely and effectively. Discography performed before nucleoplasty is associated with a risk of discitis, epidural abscess, or disc rupture (16). In addition, there were cases of back pain after nucleoplasty alone. In this case, when neuroplasty was performed with nucleoplasty, it was possible to prevent back pain due to the procedure by injecting appropriate drugs into the epidural space. No patient complained of back pain in the same case. Furthermore, through neuroplasty, it is possible to consider the neural compression caused by the disc based on the stenosis of the epidural space without the need for imaging tests such as MRI.

Regression analysis showed that the number of target levels or the method of treatment did not significantly affect treatment time or pain relief. In addition, the procedure time at the target level was 27 minutes for nucleoplasty alone and 28 minutes for combined balloon neuroplasty and nucleoplasty, showing no significant difference between the 2 groups. There was no significant difference in the procedure time, which may be due to the smooth flow of the epidural space due to the decompressed disc after nucleoplasty, making it easier to insert the catheter.

Complications, such as bleeding and spondylodiscitis, after percutaneous nucleoplasty were first reported by Rathmell et al (9). Cohen et al (17) reported that 2 out of 16 patients who underwent nucleoplasty complained of new-onset neurologic symptoms, which could be due to indirect nerve damage. In addition, performing discography before nucleoplasty may prevent nerve damage, infection, or greater nerve injury. However, in this study, the above complications did not occur in any group, and it is suggested that more studies should be conducted through a large-scale study in the future.

Limitations

This study had some limitations. First, this was a retrospective study, and there is selection bias, and it is thought that randomized control and large-scale studies are needed in the future. We hypothesize that the best way to avoid selection bias is to use randomization. Second, it is possible that the patients were assigned according to the different indications for neuroplasty and nucleoplasty. However, there was no significant difference according to the degree of central stenosis or foraminal stenosis on MRI in each group. In the case of central stenosis due to disc bulge, nucleoplasty may be preferable to balloon neuroplasty in cases of foraminal stenosis. The third limitation is that only the degree of pain was evaluated without considering the patient's pain medication before the procedure. Only the dose change before and after the procedure was identified without evaluating the type of drug being taken. Since the procedures were performed by one operator, inherent bias occurred. Moreover, since the procedure was performed only at one center, the results of the procedure may differ depending on the operator. A large-scale randomized control study will be needed in the future. In this study, it was difficult to evaluate patient satisfaction by examining only NRS and ODI, and the Zurich Claudication Questionnaire should be considered in the future.

Conclusion

This study is the first to compare pain reduction and ODI among nucleoplasty, neuroplasty, and combined balloon neuroplasty and nucleoplasty. When balloon neuroplasty and nucleoplasty were performed together, the pain reduction effect was greater, and the pain-free period was longer than those in nucleoplasty or neuroplasty alone in patients with LSS.

Consent for Publication

Written informed consent was obtained from the patient for publication of this paper and any accompanying images. A copy of the written consent is available for review by the Editor-in-Chief of this journal.

Acknowledgments

The authors wish to thank Jong Bum Choi, Ph.D., for his contributions in drafting the manuscript and revising it for important intellectual content.

Availability of Data and Materials

The authors agree to make the raw data and materials described in our manuscript freely available.

References

1. Manchikanti L, Abdi S, Atluri S, et al. An update of comprehensive evidence-based guidelines for interventional techniques in chronic spinal pain. Part II: guidance and recommendations. *Pain Physician* 2013; 16::S49-S283.
2. Park TK, Hong JH, Kim JM, et al. Factors associated with the outcome of transforaminal epidural steroid injections. *Korean J Anesthesiol* 2008; 55:298-304.
3. Donohue NK, Tarima SS, Durand MJ, Wu H. Comparing pain relief and functional improvement between methylprednisolone and dexamethasone lumbosacral transforaminal epidural steroid injections: A self-controlled study. *Korean J Pain* 2020; 33:192-198.
4. Karm MH, Choi SS, Kim DH, et al. Percutaneous epidural adhesiolysis using inflatable balloon catheter and balloon-less catheter in central lumbar spinal stenosis with neurogenic claudication: A randomized controlled trial. *Pain Physician* 2018; 21:593-606.
5. Ren D, Zhang Z, Sun T, Li F. Effect of percutaneous nucleoplasty with coblation on phospholipase A2 activity in the intervertebral disks of an animal model of intervertebral disk degeneration: a randomized controlled trial. *J Orthop Surg Res* 2015; 10:38.
6. Singh V, Piryani C, Liao K. Role of percutaneous disc decompression using coblation in managing chronic discogenic low back pain: A prospective, observational study. *Pain Physician* 2004; 7:419-425.
7. Lurie J, Tomkins-Lane C. Management of lumbar spinal stenosis. *BMJ* 2016; 352:h6234.
8. Shin WS, Ahn DK, Kim MJ, Cho KJ, Go YR. Influence of epidural steroid injection on adrenal function. *Clin Orthop Surg* 2019; 11:183-186.
9. Manchikanti L, Falco FJ, Benyamin RM, et al. An update of the systematic assessment of mechanical lumbar disc decompression with nucleoplasty. *Pain Physician* 2013; 16:SE25-SE54.
10. Masala S, Massari F, Fabiano S, et al. Nucleoplasty in the treatment of lumbar diskogenic back pain: One year follow-up. *Cardiovasc Intervent Radiol* 2007; 30:426-432.
11. Eichen PM, Achilles N, Konig V, et al. Nucleoplasty, a minimally invasive procedure for disc decompression: A systematic review and meta-analysis of published clinical studies. *Pain Physician* 2014; 17:E149-E173.
12. Calisaneller T, Ozdemir O, Karadeli E, Altinors N. Six months post-operative clinical and 24 hour post-operative MRI examinations after nucleoplasty with radiofrequency energy. *Acta Neurochir (Wien)* 2007; 149:495-500.
13. Akbas M, Elawamy AR, Salem HH, Fouad AZ, Abbas NA, Dagistan G. Comparison of 3 approaches to percutaneous epidural adhesiolysis and neuroplasty in post lumbar surgery syndrome. *Pain Physician* 2018; 21:E501-E508.
14. Kim SH, Choi WJ, Suh JH, et al. Effects of transforaminal balloon treatment in patients with lumbar foraminal stenosis: A randomized, controlled, double-blind trial. *Pain Physician* 2013; 16:213-224.
15. Oh Y, Kim DH, Park JY, et al. Factors associated with successful response to balloon decompressive adhesiolysis neuroplasty in patients with chronic lumbar foraminal stenosis. *J Clin Med* 2019; 8:1766.
16. Wu B, He X, Peng BG. Pyogenic discitis with an epidural abscess after cervical analgesic discography: A case report. *World J Clin Cases* 2020; 8:2318-2324.
17. Bhagia SM, Slipman CW, Nirschl M, et al. Side effects and complications after percutaneous disc decompression using coblation technology. *Am J Phys Med Rehabil* 2006; 85:6-13.

© 2022. This work is published under
https://creativecommons.org/licenses/by-nc/4.0/ (the “License”).
Notwithstanding the ProQuest Terms and Conditions, you may use this content
in accordance with the terms of the License.